

# Interstitial lung disease secondary to oxaliplatin-raltitrexed based chemotherapy

Luca Gauci, Claudia Scerri, Maria Mifsud, Jonathan Gauci

FOLFOX is a widely used regimen in the management of gastrointestinal malignancies and is a combination of 5-fluorouracil (5-FU), folinic acid, and oxaliplatin. Raltitrexed is an antifolate thymidylate synthase inhibitor which is used as an alternative when 5-FU is not tolerated. Here we present a case of interstitial lung disease as a rare side-effect of oxaliplatin and raltitrexed. Not much is known about the pathophysiology of the condition and most information available in the literature is taken from published case reports.

**Dr Luca Gauci, MD**

Department of Medicine,  
Mater Dei Hospital,  
Msida, Malta

**Dr Claudia Scerri, MD**

Department of Medicine,  
Mater Dei Hospital,  
Msida, Malta

**Dr Maria Mifsud  
MD, MRCP(UK)**

Department of Haematology & Oncology,  
Sir Anthony Mamo Oncology Centre,  
Msida, Malta

**Dr Jonathan Gauci  
MD, MRCP(UK)**

Department of Medicine,  
Mater Dei Hospital,  
Msida, Malta

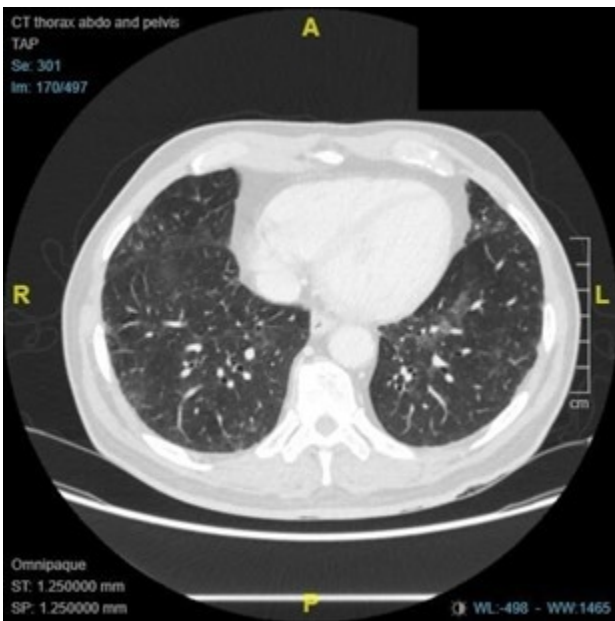
FOLFOX is a chemotherapeutic regimen consisting of the fluoropyrimidine 5-fluorouracil (5-FU), folinic acid, and the third-generation platinum compound oxaliplatin. Its main use is in colorectal cancer, however, it is also indicated for use in locally advanced (inoperable) or metastatic oesophageal or gastric cancer<sup>1</sup>. Those patients who develop coronary vasospasm and cardiotoxicity with 5-FU based regimens are switched to raltitrexed.<sup>2</sup> Recent studies have shown that gastric cancer with a high expression of thymidylate synthase (TS) mRNA levels can be efficiently managed with raltitrexed.<sup>3</sup> Phase 2 clinical trials are currently underway to assess the response rate, overall survival, and progression-free survival of raltitrexed in inoperable gastric cancer.<sup>4</sup>

In general, chemotherapy is associated with several side effects including myelosuppression, allergic reactions, mucositis, gastrointestinal disturbance, infertility, and others. Oxaliplatin may cause neurotoxicity (cold-associated dysaesthesia and peripheral sensory neuropathy) whereas fluoropyrimidines may cause coronary artery spasm, cardiotoxicity, and palmar/

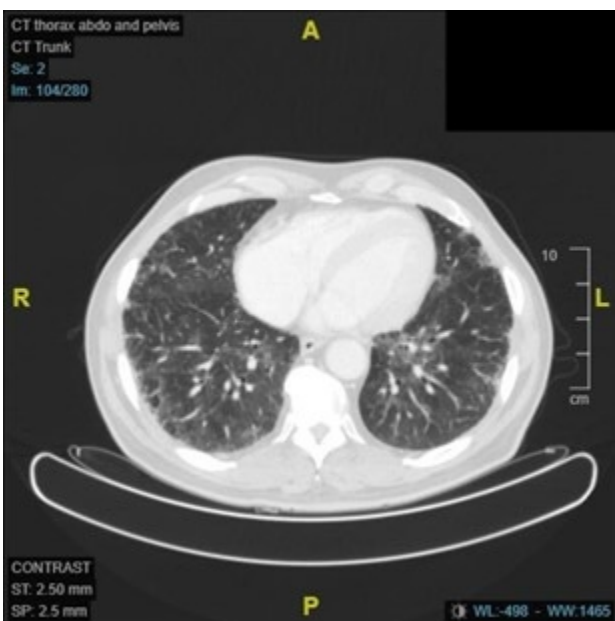
plantar erythema.<sup>1</sup> Raltitrexed may be associated with liver impairment.<sup>5</sup> There are very few documented cases of lung toxicity attributed to these regimens. Increasing awareness helps clinicians maintain a high index of suspicion and initiate effective treatment promptly to reduce morbidity and mortality.

## CASE REPORT

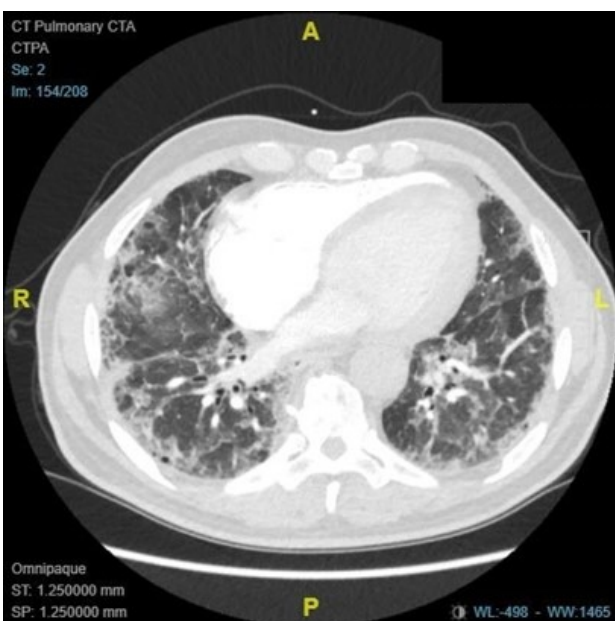
A 72-year-old Maltese gentleman presented with dyspepsia and melaena in June 2021. A gastroscopy was performed, and a lesion in the body of the stomach was visualized and biopsied. Staging CT showed extensive carcinoma of the stomach with peritoneal metastasis and spread to the regional, abdominal, and retroperitoneal lymph nodes. Histology was reported as moderately differentiated intestinal-type adenocarcinoma of the stomach body. Thus a diagnosis of stage IV gastric cancer was made. He was planned for 12 cycles of 2 weekly FOLFOX chemotherapy at 80% of the full dose, with palliative intent.



**Figure 1** Baseline CT Thorax pre-treatment



**Figure 2** Re-staging CT Thorax after cycle 8



**Figure 3** CT Pulmonary Angiography after clinical deterioration

The patient did not have any underlying respiratory conditions. His medical history included gout, hypertension, glaucoma, and pancreatitis. There were no known drug allergies. He had no previous exposure to asbestos or other occupational hazards. He was an ex-smoker with a 30-pack-year history. His baseline Eastern Cooperation Oncology Group/World Health Organization (ECOG/WHO) performance status was 1 - fully independent and ambulatory, with limitations only in physically strenuous activities.

Baseline thoracic imaging at diagnosis showed tiny bilateral bullae and non-specific mosaic attenuation in the lower lung lobes (Figure 1). He underwent 4 cycles of FOLFOX chemotherapy from July 2021 to September 2021, with very minimal side effects and a good tolerability profile. For the 5th cycle of chemotherapy, 5-FU was omitted due to central compressive chest pain experienced during 5-FU infusion. The latter was switched to raltitrexed and was subsequently given together with oxaliplatin every 3 weeks at a reduced dose of 75% due to low creatinine clearance.

A re-staging CT (Figure 2) after cycle 8 revealed early ground glass and emphysematous changes as well as intra-lobar septal thickening. Due to good oncological response on imaging and down-trending tumour markers, no changes were done to the treatment, and another cycle was given.

The patient presented acutely before his 10th cycle, with severely reduced exercise tolerance, exertional shortness of breath, and dry cough. These symptoms had started a few days after cycle 9 and were limiting most of his activities of daily living. His ECOG/WHO performance status was now measured at 3 - semi-dependent with limited self-care and severely restricted mobility. He denied any other symptoms. Clinically his oxygen saturation at rest was 95% on room air with a significant desaturation after a 6-minute walk test. He had fine bi-basal inspiratory crepitations up to mid-zones on chest examination. His blood results were within normal limits and were not indicative of an active infective process.

Repeat imaging of the thorax excluded pulmonary thrombosis, however, revealed extensive ground glass and emphysematous changes in the lower lobes with intralobular septal thickening in the lung bases (Figure 3). A preliminary diagnosis of chemotherapy-induced interstitial pneumonia was made. Spirometry (Figure 4) showed a severe restrictive abnormality, with an FEV1 of 1.39L (52%) and an FVC of 1.39L (40%).

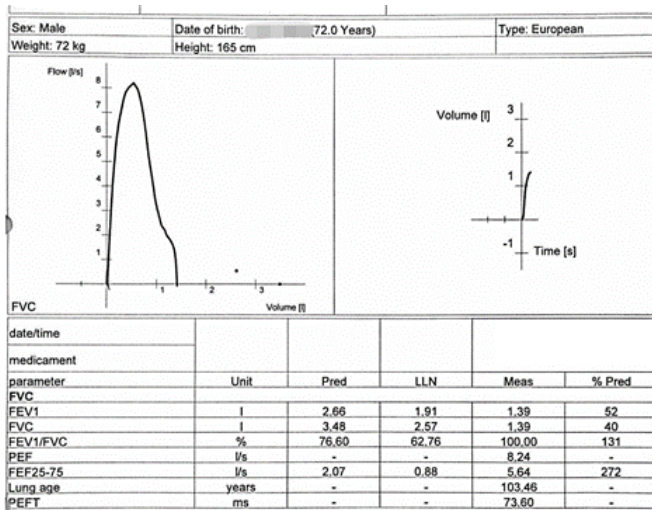


Figure 4 Baseline spirometry before steroid treatment

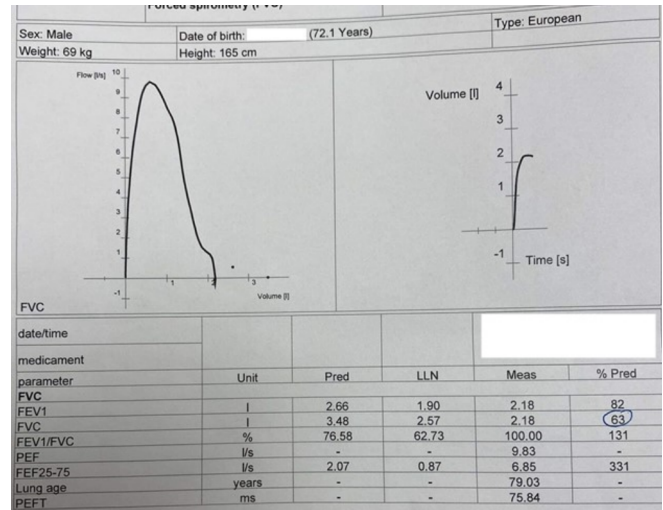


Figure 5 Repeat spirometry after steroid treatment

The case was discussed within a multidisciplinary team and concluded the discontinuation of all chemotherapeutic agents, including oxaliplatin and raltitrexed, due to chemotherapy-induced interstitial pneumonia. Chemotherapy was stopped and 4mg dexamethasone was given daily. After 5 weeks of treatment, some improvement in exercise tolerance was reported and a repeat spirometry (Figure 5) showed an increase in FEV1 and FVC by 30% and 23%, respectively. The spirometry technique was poor on both occasions as the patient could only exhale for one second. In fact, the FVC is equal to FEV1 in both cases.

The dose of dexamethasone was tailed down slowly by 1mg every 4 weeks. Follow up imaging (Figure 6) performed 3 months after diagnosis showed near-complete resolution of changes of organising pneumonia with post-interstitial pneumonitis scarring, moderate basal predominant lung fibrosis, and traction bronchiectasis. He was later started on long-term oxygen therapy due to persistent dyspnoea.

His general condition deteriorated over the following weeks with worsening dyspnoea and saturations below 50% on room air. Unfortunately he passed away due to respiratory failure and progression of malignant disease.

## DISCUSSION

The summary of product characteristics lists interstitial lung disease and pulmonary fibrosis as rare side-effects of oxaliplatin with a frequency of  $\geq 1/10000$  and  $< 1/1000$ .<sup>6</sup> Homma et al report an incidence of 0.2% (11/5008 cases) in Japan in

2007.<sup>7</sup> Trials involving oxaliplatin reported an incidence of pulmonary fibrosis and grade IV pulmonary toxicity in less than 1%.<sup>11</sup> Several other reports note that the actual incidence might be higher, because many cases remain under-diagnosed or missed due to the relatively mild symptomatology of most patients. Unfortunately more than half of the reported cases were fatal.<sup>8,11</sup>

Both oxaliplatin and raltitrexed can cause pulmonary toxicity in the form of diffuse alveolar damage, subacute interstitial pneumonia and fibrosis.<sup>12</sup> Howlett et al report a case of an acute exacerbation of interstitial lung disease from raltitrexed therapy.<sup>13</sup>

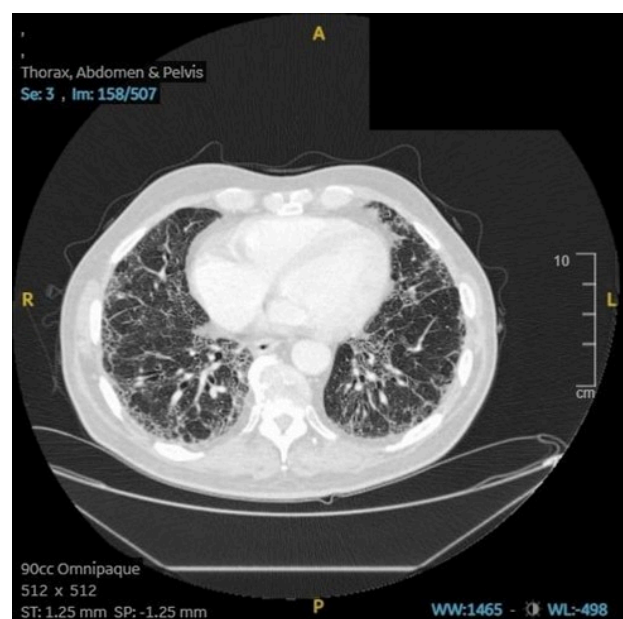


Figure 6 Repeat CT Thorax 3 months after treatment

Although the exact pathogenesis of drug-induced lung injury is unknown, several mechanisms have been proposed, including cytotoxic and immunological reactions.<sup>7,8</sup> Cytotoxic reactions are the dose-dependent effects exerted directly on the cells of the lung by the chemotherapy or its metabolites. Immunological reactions consist of type I (anaphylactic) and type IV (delayed) hypersensitivity reactions, with the incidence increasing after each cumulative dose.<sup>7</sup> Another school of thought is that oxaliplatin reduces the glutathione stores, making organs susceptible to oxidative damage.<sup>7,8,11</sup> One particular case describes a dramatic improvement of symptoms upon initiation of N-acetylcysteine which is used to replenish glutathione.<sup>9</sup> Pavlović et al mention the use of imatinib for its lung fibroblast inhibition in the management of interstitial lung disease.<sup>8</sup>

Currently there are no randomised controlled trials on the most effective management of drug-induced interstitial lung disease. Most documented cases have been managed with prompt cessation of the culprit drug followed by corticosteroid therapy. Before commencing corticosteroids on a patient with suspected drug-induced lung injury, it is essential to exclude underlying infection. Homma et al mention the role of bronchoalveolar lavage fluid which plays a pivotal role in the diagnosis of drug-induced lung injury (presence of lymphocytes ± eosinophils) and in the exclusion of infection. However it might be difficult to obtain in patients who are unfit for a bronchoscopy due to respiratory failure. In such cases, an induced-sputum sample may prove useful.<sup>7</sup> This is not performed locally.

A temporal relationship between the initiation of a drug and the onset of signs and/or symptoms may be the only indicator of a suspected drug-induced reaction. Since chemotherapy is usually administered as a combination, it may be difficult to identify which is the main causative agent. Any one of the agents may contribute towards the toxicity, to a greater or lesser extent. Some papers mention the use of drug lymphocyte stimulation testing (DLST), but a positive result does not always mean the drug is the cause.<sup>7</sup> Diffuse alveolar damage is thought to be the main histopathological finding in over 50% of post-mortem studies.<sup>10</sup>

## SUMMARY BOX

- Interstitial lung disease following FOLFOX or FOLFIRI is an uncommon but life-threatening complication.
- Pulmonary toxicity is an important complication associated with many of the antineoplastic agents in use. It should be considered in any patient undergoing chemotherapy who presents with dyspnoea and hypoxia in order to try and reduce the associated morbidity and mortality.
- Care must be taken regarding the onset of interstitial lung disease and a multidisciplinary approach is essential for the management of such complications.

A recent literature review has included 28 cases of oxaliplatin-induced lung toxicity, 16 of which resulted in a fatal outcome.<sup>8</sup> Age (>60 years), male gender, history of smoking, arterial hypertension, pre-existing lung conditions, and chronic kidney disease are thought to increase the risk of drug-induced lung injury.<sup>7-9,11</sup>

Homma et al suggest careful monitoring with frequent blood tests and chest radiographs in patients on oxaliplatin-containing regimens. Those patients who develop new-onset respiratory symptoms (dry cough, dyspnoea) or signs (crackles, new infiltrates on imaging) should be discussed with the Respiratory specialists. The causative agents should be stopped and the necessary investigations performed. Corticosteroids should be started without delay if interstitial lung disease is suspected.<sup>6</sup>

## CONCLUSIONS

Pulmonary toxicity is a rare (sometimes fatal) side-effect of oxaliplatin and raltitrexed therapy with only a few documented cases worldwide. There is a lack of awareness about the condition which should be addressed. All chemotherapeutic protocols with these chemotherapeutic agents should alert the prescriber regarding the possibility of lung damage as a possible side-effect of therapy.



## REFERENCES

1. Oxaliplatin & Modified De Gramont (FOLFOX). (February 2021). Royal Surrey NHS UK <https://www.royalsurrey.nhs.uk/download.cfm?doc=docm93jjm4n11321.pdf&ver=25956>
2. Tomudex 2 mg powder for solution for infusion - Summary of Product Characteristics (SmPC) - (emc). (2021) Electronic Medicines Compendium. <https://www.medicines.org.uk/emc/product/5500/smpc>
3. Shen J, Wang H, Wei J, Yu L, Xie L, Qian X, Zou Z, Liu B, Guan W. Thymidylate synthase mRNA levels in plasma and tumor as potential predictive biomarkers for raltitrexed sensitivity in gastric cancer. *International Journal of Cancer* 2012;131:(6)E938–45.
4. Raltitrexed and Paclitaxel for Gastric or Gastroesophageal Junction Adenocarcinoma - Full Text View - ClinicalTrials.gov. (n.d.). ClinicalTrials.Gov. <https://clinicaltrials.gov/ct2/show/NCT03083613>
5. Raltitrexed & Oxaliplatin. (January 2019). Royal Surrey NHS UK <https://www.royalsurrey.nhs.uk/download.cfm?doc=docm93jjm4n7475.pdf&ver=15760>
6. Oxaliplatin 5mg/ml concentrate for solution for infusion - Summary of Product Characteristics (SmPC) - (emc). (2020, October). Electronic Medicines Compendium. <https://www.medicines.org.uk/emc/product/11052/smpc>
7. Homma T, Kurokawa M, Yamamoto Y, Matsukura S, Ieki K, Suzuki S, Odaka M, Watanabe S, Yamaguchi M, Adachi M. Oxaliplatin-induced lung injury with allergic reaction. *Chinese Journal of Cancer Research* 2011;23,(3) 232–5.
8. Pavlović, M Oxaliplatin Induced Pulmonary Fibrosis: A Case Report. *Acta Clinica Croatica*. 2020; 59:761-4
9. Wilcox B E, Ryu J H, Kalra S. Exacerbation of pre-existing interstitial lung disease after oxaliplatin therapy: A report of three cases. *Respiratory Medicine*. 2008;102;(2)273–9.
10. Hannan L M, Yoong J, Chong G, McDonald CF. Interstitial lung disease in a patient treated with oxaliplatin, 5-fluorouracil and leucovorin (FOLFOX) for metastatic colorectal cancer. *Radiology and Oncology*. 2012;46:(4) 360 -2.
11. Moskovitz M, Wollner M, Haim N. Oxaliplatin-Induced Pulmonary Toxicity in Gastrointestinal Malignancies: Two Case Reports and Review of the Literature. *Case Reports in Oncological Medicine* 2015, 1–5.
12. Carreres-Prieto M, López-Sisamón, D, Layos-Romero L. Interstitial lung disease induced by raltitrexed-oxaliplatin based chemotherapy for colorectal cancer: a case report. *Farmacia Hospitalaria: Organo Oficial De Expresion Cientifica De La Sociedad Espanola De Farmacia Hospitalaria*. 2015;39:(2)118–119.
13. Howlett S, Aul R, Pinato DJ. Acceleration of interstitial lung disease induced by raltitrexed. *Journal of Oncology Pharmacy Practice*. 2020;26:(5)1241-3.