

# An Unusual Cause for Fever: A Case Report on Microscopic Polyangiitis

Valentina Fenech, Norma Pavia, Michela Frendo

## Abstract

Microscopic polyangiitis is a small-vessel vasculitis which results in pauci-immune necrotizing inflammation of blood vessel walls. In this report, we describe a case of microscopic polyangiitis in a 65-year old female who presented with a one month history of lower back pain followed by reduced appetite, weight loss and fever. An immunology screen detected perinuclear anti-neutrophil cytoplasmic antibodies with myeloperoxidase specificity in the serum. A renal biopsy was obtained because of mild proteinuria on urinalysis and revealed a small vessel vasculitis consistent with microscopic polyangiitis. She was started on treatment with glucocorticoids and cyclophosphamide which resulted in a positive clinical response, with resolution of fever and improvement in her inflammatory markers. Currently she is stable and since starting treatment, she has not had any relapses or flare ups.

## Keywords

Microscopic polyangiitis; Fever; Glucocorticoids; Cyclophosphamide

## Introduction

Microscopic polyangiitis (MPA) is a rare condition associated with a significant burden of disease. Its non-specific presentation can represent a diagnostic challenge and lead to a delay in initiation of treatment. We report the case of a patient with MPA as an important clinical reminder to maintain a high index of suspicion in patients with persistent fever.

## Case presentation

A 65-year old lady presented with a one month history of worsening exertional low back pain radiating to both lower limbs. There was no nocturnal pain or sphincter dysfunction. A Doppler Ultrasound of both lower limbs ruled out deep venous thrombosis and a Lumbosacral spine X-ray showed degenerative disc disease. The patient was diagnosed with mechanical back pain and discharged home on analgesia.

She presented again ten days later, with persistent low back pain together with myalgias in both of her calves. This time the pain was associated with reduced appetite and 2kg weight loss. She also had an on-going fever of up to 38.2°C present since seven days.

She was otherwise hemodynamically stable and her physical examination was unremarkable. She had no rashes, no arthritis, no localised tenderness or focal neurological deficits.

Her past medical history included gastroesophageal reflux disease and hypothyroidism. She had no significant travel, social and family history.

## Investigations

Initial investigations revealed a raised White cell count ( $22.66 \times 10^9/L$ ), Erythrocyte sediment rate (112mm1stHr) and C-reactive protein (125.9mg/L)

### Valentina Fenech\*

Department of Medicine  
Mater Dei Hospital  
Msida, Malta  
Valentina.fenech@gov.mt

### Norma Pavia

Department of Neurosciences  
Mater Dei Hospital  
Msida, Malta

### Michela Frendo

Department of Rheumatology  
Mater Dei Hospital  
Msida, Malta

\*Corresponding Author

## Case Report

in-keeping with a marked inflammatory response. Haemoglobin was low (8.9g/dL) and haematinics showed low iron and folate stores. Urinalysis confirmed the presence of protein (25mg/dL) and erythrocytes (25mg/dL).

Infection was the primary suspected diagnosis. A Chest radiograph was taken and specimens of blood, urine and sputum were obtained and analysed for culture and sensitivity. Following this, the patient was started on empirical treatment with intravenous antibiotics.

However, the fever persisted and inflammatory markers remained elevated. A Computed Tomography scan of the Thorax, Abdomen and Pelvis was performed to assess for occult infection including abscess formation or malignancy. The scan was grossly normal except for mild thickening of the gastroesophageal junction. Malignancy was ruled out after a gastroscopy was normal. A transthoracic echocardiogram was also performed which did not reveal any vegetations.

Due to a progressive anaemia and persistent leucocytosis and thrombocytosis a diagnosis of

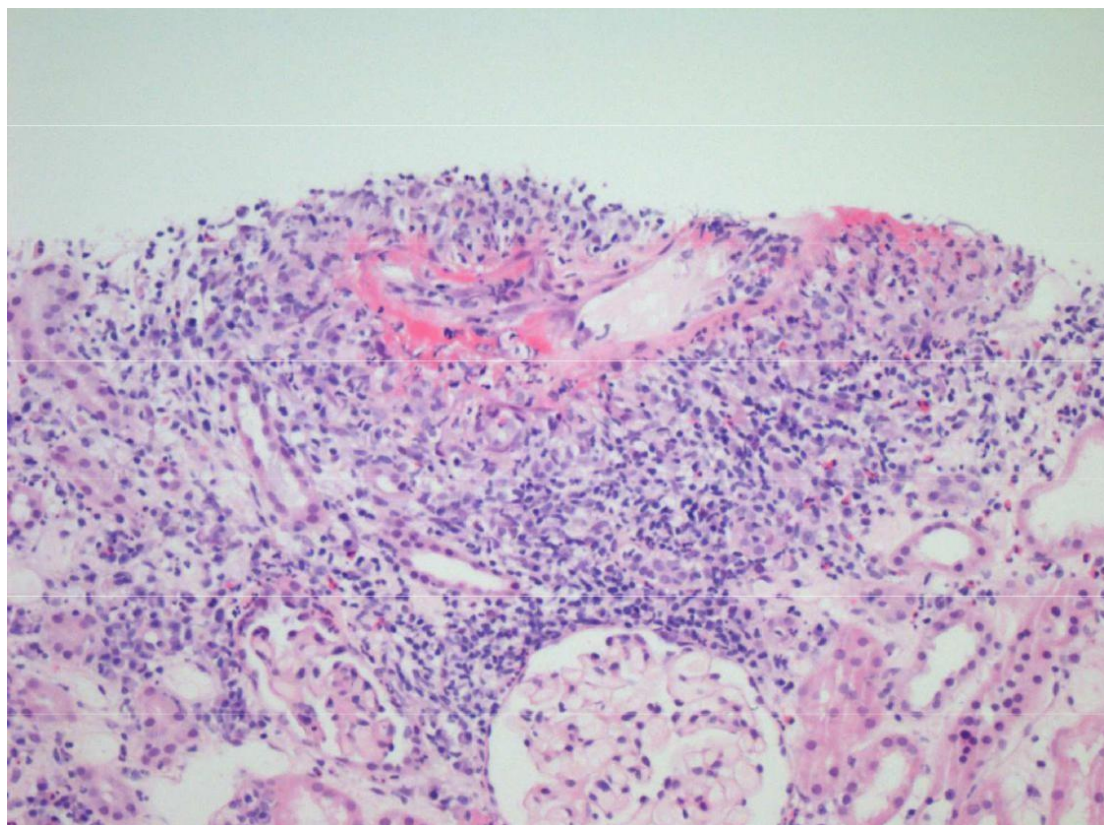
myelodysplasia was considered. However, JAK2-V617F and BCR-ABL mutations were negative and a blood film showed only reactive-looking features. No monoclonal bands were detected on serum protein electrophoresis either.

On immunology screen, a high-titre of Myeloperoxidase-anti-neutrophil cytoplasmic antibodies (MPO-ANCA) (199.7U/mL) was detected, whilst other components of the immunology screen including Extractable nuclear antigen, Anti-nuclear antibody, Complement, Aldolase and Creatine kinase were normal. A viral screen was also negative.

In view of the history of proteinuria, a renal biopsy was obtained which confirmed the presence of a pauci-immune necrotizing small-vessel vasculitis. A total of twenty-five glomeruli were sampled and examined under light and electron microscopy (Figure 1 and 2). Indirect immunofluorescence was also used which demonstrated weak IgM-staining in mesangial areas whilst IgG, IgA and C3 were negative.

### **Figure 1:** Light microscopy of renal biopsy specimen

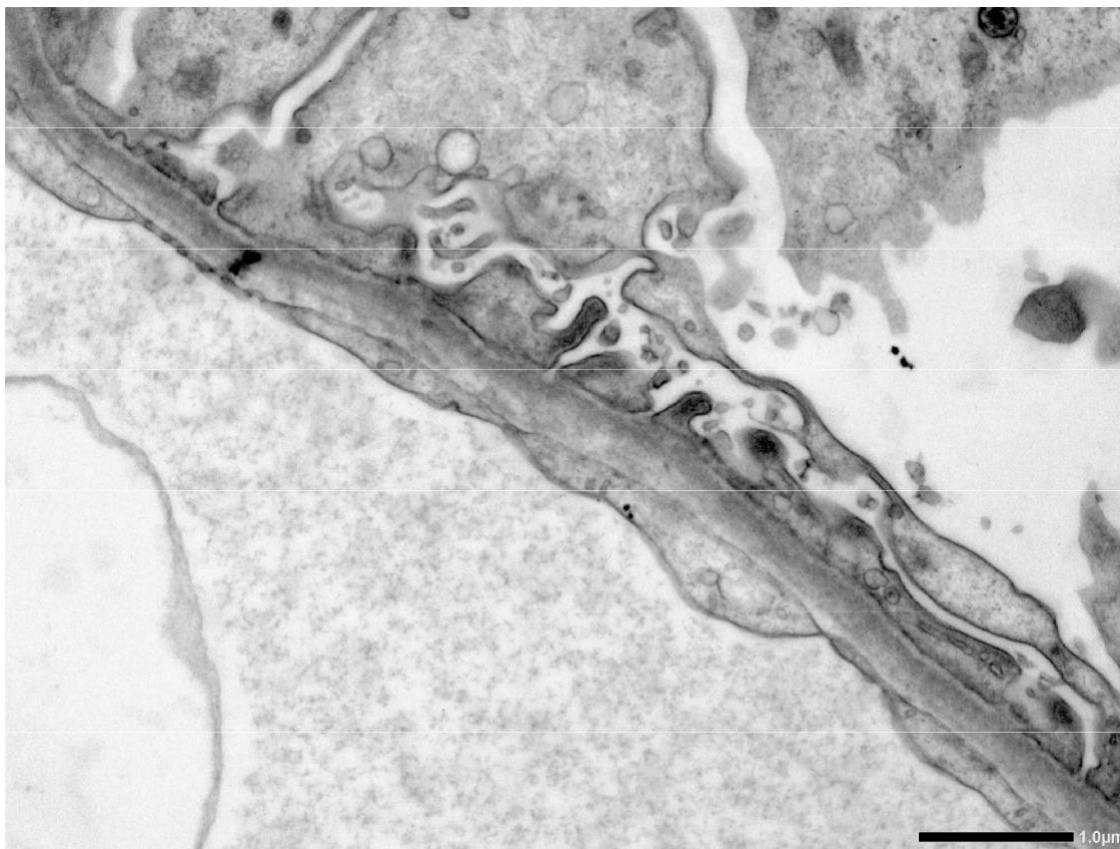
*Light microscopy of renal biopsy specimen which shows histopathological evidence of transmural fibrinoid necrosis of a small artery with sparing of glomerulus (Haematoxylin & eosin stain).*



## Case Report

### **Figure 2:** Electron microscopy of renal biopsy specimen

Electron microscopy of renal biopsy specimen which shows mild endothelial swelling and loss of fenestrations. The basement membrane and podocyte layer are normal.



### **Treatment and Outcome**

She received three pulses of intravenous methylprednisolone 500mg daily followed by a course of oral prednisolone at an initial dose of 1mg/kilogram/day (patient weighed 46kg) with good clinical effect. She was discharged on a tapering dose regime of oral prednisolone with calcium and vitamin D supplementation. She also underwent a Dual-energy X-ray absorptiometry scan with a view to starting bisphosphonate treatment after dental review and clearance.

Following education and counselling, she received intravenous cyclophosphamide (CP) with prophylactic co-trimoxazole and mercaptoethane sulfonate.

Since her diagnosis about one month ago, she is currently tailing off her steroids and undergoing treatment with 600mg of CP for a total of six doses.

### **Discussion**

MPA is a MPO-ANCA-positive vasculitis which causes a pauci-immune

necrotising inflammation of predominantly small blood vessels.<sup>1</sup>

The incidence of MPA in Europe ranges from 2.4 to 10.1 per million, whilst the prevalence ranges from 25.1 to 94 per million and shows an increase with age.<sup>2</sup>

MPA mainly presents with non-specific symptoms such as fever, myalgia, anorexia, weight loss and night sweats.<sup>3</sup> Therefore tissue-biopsy evidence of vasculitis is the gold standard for diagnosis.

MPA has the capacity to affect any organ but it has a predilection for the kidneys and lungs.<sup>3</sup> Renal manifestations include haematuria, proteinuria, red cell casts and focal segmental rapidly progressive glomerulonephritis.<sup>3</sup> The latter condition is life-threatening and leads to a rapid deterioration in glomerular filtration rate of at least 50% over weeks or days and extensive glomerular crescent formation.<sup>3</sup> Renal involvement in ANCA-associated vasculitis (AAV) has a worse prognosis in MPO-ANCA patients and glomerular sclerosis is associated with worse outcomes.<sup>4-5</sup>

The most important pulmonary manifestation of MPA is alveolar haemorrhage which occurs in about a third of MPA patients and it can be severe and life-threatening.<sup>3</sup>

New-onset organ-threatening or life-threatening disease is treated with glucocorticoids in combination with CP or rituximab (RX) which have similar efficacy profiles in induction of disease remission.<sup>6</sup> Pulse intravenous CP is preferred to daily oral CP as it results in a lower cumulative dose and is associated with less side-effects.<sup>7</sup>

Non-organ-threatening disease is treated with glucocorticoids in combination with methotrexate (MTX) or mycophenolate mofetil (MMF) whilst plasma exchange is reserved for patients with rapidly progressive renal failure or severe pulmonary haemorrhage.<sup>6</sup>

Disease remission should be maintained with a combination of low-dose glucocorticoids and immunosuppressive therapy which include azathioprine (AZA), RX, MTX and MMF.<sup>6</sup> The glucocorticoid-immunosuppressive treatment should be continued for a minimum length of 24 months and early cessation increases risk of relapse.<sup>6</sup>

AAV demonstrate a 2.7-fold increased mortality risk compared with the general population.<sup>8</sup> MPA long-term prognosis is less severe but relapses are frequent and can occur years after initial diagnosis.<sup>9</sup> The main factors affecting survival are age, renal involvement and burden of treatment.<sup>9</sup> Early diagnosis, treatment and prolonged follow-up are crucial to overcome the pitfalls related to MPA and improve patient outcomes.

### Acknowledgements

We would like to thank Dr. Stephen Holwill for providing us with the images used in this case report.

### References

1. Jennette JC, Falk RJ, Bacon PA, et al. 2012 Revised International Chapel Hill Consensus Conference Nomenclature of Vasculitides. *Arthritis Rheum.* 2013; **65**:1–11.
2. Watts RA, Mahr A, Mohammad AJ, Gatenby P, Basu N, Flores-Suárez LF. Classification, epidemiology and clinical subgrouping of antineutrophil cytoplasmic antibody (ANCA)-associated vasculitis. *Nephrol Dial Transplant* 2015;**30**(1):i14-22.
3. Villiger PM, Guillevin L. Microscopic polyangiitis: Clinical presentation. *Autoimmun Rev* 2010 Oct;**9**(12):812-9.
4. Mohammad AJ, Segelmark M. A population-based study showing better renal prognosis for proteinase 3 antineutrophil cytoplasmic antibody (ANCA)-associated nephritis versus myeloperoxidase ANCA-associated nephritis. *J Rheumatol* 2014;**41**:1366–73.
5. Ford SL, Polkinghorne KR, Longano A, et al. Histopathologic and clinical predictors of kidney outcomes in ANCA-associated vasculitis. *Am J Kidney Dis* 2014;**63**:227–35.
6. Yates M, Watts RA, Bajema IM, et al. EULAR/ERA-EDTA recommendations for the management of ANCA-associated vasculitis. *Annals of the Rheumatic Diseases* 2016;**75**:1583-1594.
7. De Groot K, Adu D, Savage COS. The value of pulse cyclophosphamide in ANCA-associated vasculitis: Meta-analysis and critical review. *Nephrol Dial Transplant* 2001;**16**:2018–27.
8. Tan JA, Dehghan N, Chen W, Xie H, Esdaile JM, Avina-Zubieta JA. Mortality in ANCA-associated vasculitis: a meta-analysis of observational studies. *Annals of the Rheumatic Diseases* 2017;**76**:1566-74.
9. Corral-Gudino L, Borao-Cengotita-Bengoia M, Del Pino-Montes J, Lerma-Márquez JL. Overall survival, renal survival and relapse in patients with microscopic polyangiitis: a systematic review of current evidence. *Rheumatology* 2011;**50**:1414–23.