

‘Brenner tumour – The rare malignant variant’

Maria Petra Agius, Mandy Collict, Romina Cini Custo, Miljan Milic,
Max Dingli, Albert Scerri

Abstract

Brenner tumors comprise an uncommon subtype of the surface epithelial-stromal tumor group of ovarian neoplasms. While most are benign, some can be malignant, and we report such a case and its treatment.

Brenner tumours were first described by MacNoughton Jones in 1898 in his paper ‘Uterine fibroid with anomalous ovarian tumour.’¹ In 1907, Fritz Brenner published his article ‘Des oophorona folliculare’ because of the resemblance of the epithelioid nests that Brenner found in his tumour, to Graafian follicles.² The semblance to Graafian follicles underpinned Fritz Brenner’s classification of Brenner tumours as a variant of granulosa cell tumour. In 1932, Meyer, revisited the topic of Brenner tumours and clarified that they are different from granulosa cell tumours.³ However, Brenner became aware of such a publication, 24 years later and did not publish any other articles on this subject.

The incidence of ovarian cancer is 11.7 per 100,000 women per year.⁴ Ovarian Brenner tumours represent a rare epithelial ovarian neoplasm accounting for approximately 1–2% of all ovarian tumours. Brenner tumours can be sub-classified into benign, borderline or malignant variants.⁵ Malignant Brenner tumours are extremely rare, comprising less than 5% of all Brenner tumours. Malignant Brenner tumour was first reported in 1945 by von Numeras.⁶

A 70-year-old lady was referred by her family doctor with a large abdominal mass associated with a 19-kilo weight loss over 3 months, and 1-month history of constipation. General examination revealed a large hard mass, extending up to the umbilicus. An ultrasound scan showed a pelvic mass, probably of ovarian origin. Her Risk of Malignancy Index (RMI) score, which is calculated as the product of the ultrasound findings score, menopausal status and ca125 levels, added up to 1580. This was followed by computed tomographic assessment of the trunk, which revealed a large inhomogeneous mass measuring 16cm by 14cm by 17cm, originating from the pelvic cavity, with enlarged pelvic lymph nodes, together with an ill-defined hypovascular nodule measuring 8mm in diameter in the liver. The pelvic mass was further characterised by magnetic resonance imaging and was found to be arising from the left ovary.

Maria Petra Agius MD*

Department of Obstetrics and Gynaecology
Mater Dei Hospital
Msida, Malta
mariapetra.agius@gmail.com

Mandy Collict MD Msc MRCSED

Department of Obstetrics and Gynaecology
Mater Dei Hospital
Msida, Malta

Romina Cini Custo MD MRCOG DFSRH

Department of Obstetrics and Gynaecology
Mater Dei Hospital
Msida, Malta

Miljan Milic MD

Department of Pathology
Mater Dei Hospital
Msida, Malta

Max Dingli MD MRCOG

Department of Obstetrics and Gynaecology
Mater Dei Hospital
Msida, Malta

Albert Scerri MD FRCOG (UK)

Department of Obstetrics and Gynaecology
Mater Dei Hospital
Msida, Malta

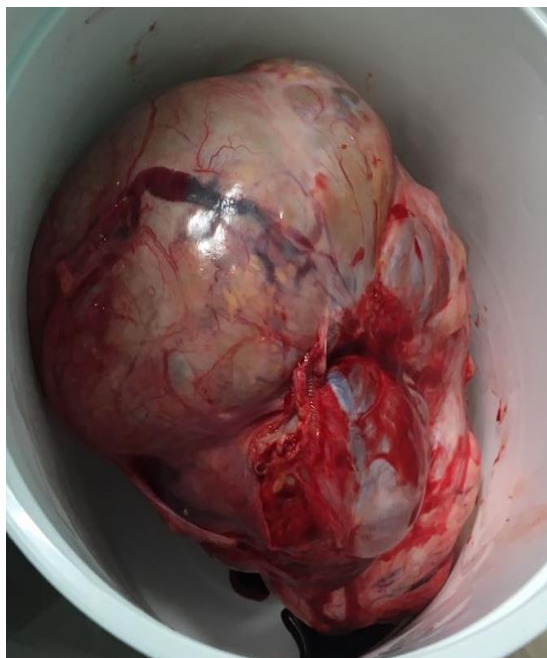**Corresponding Author*

Case Report

Multiple peritoneal metastases and ascites were also seen. The liver was further studied by magnetic resonance imaging, which showed two indeterminate lesions in the right hepatic lobe. Ultrasound guided biopsy of the liver lesion was then performed. A core biopsy was obtained from the larger lesion and the histological and the immune-histochemical findings revealed metastatic carcinoma of urothelial nature. The immunohistochemistry profile was positive for BRCK, CK7, p63 and p53. It was inhibin and oestrogen receptor negative.

Total abdominal hysterectomy with bilateral salpingo-oophorectomy and omentectomy were performed via a midline laparotomy. Intra-operatively, an 18 cm-left ovarian tumour was found illustrated in Figure 1. On cross section, the mass showed a partly solid ossified tissue and partly cystic lesion. On sectioning of the cystic component, a multi-cystic lesion filled with thick yellowish fluid and multiple papillary structures were visible on the inner surface.

Figure 1: Image showing the left smooth adnexal mass measuring 20cm by 13.5cm by 12.5cm. The fallopian tube is also visible, measuring 9cm by 3cm.



The histological result confirmed a malignant Brenner tumour limited to the ovary, with angiolymphatic invasion (figure 2), pT1c3NxM1b, FIGO IVB.

Histologically, the left ovarian tumour was composed of sheets and nests of urothelial cells with intra-tumour micro cyst formation. Fused papillary fronds were focally identified projecting into the cyst lumina. Stromal desmoplasia was identified in areas, associated with focal dystrophic calcification and ossification. The urothelial cells showed mild-to-moderate nuclear pleomorphism and were briskly mitotically active as shown in figure 3. Areas of intra-tumoural necrosis were present.

The other ovary, uterus and cervix showed no evidence of involvement by tumour. The case was discussed at the Gynaecology Multidisciplinary Team Meeting and the patient was referred for further oncological care. The patient is currently receiving six cycles of adjuvant paclitaxel and cisplatin at 3-weekly intervals.

Figure 2: Image illustrating vascular invasion of tumour cells.

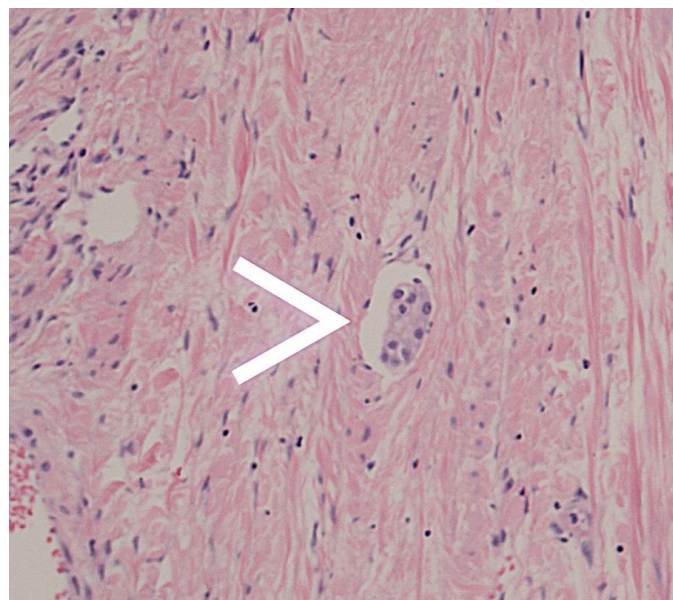
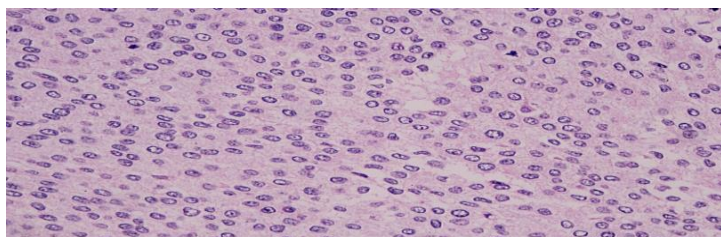


Figure 3: Image illustrating actively dividing cell and prominent nuclei within cells.



Hull and Campbell, in 1973, have proposed that a set of histological criteria should be present to diagnose malignant Brenner tumour. This requires the presence of malignant histological features forming irregular epithelial nests, benign or borderline Brenner tumour elements and stromal invasion.⁷

The prognosis of such malignancies is relatively poor in view of late presentation and rarity of the disease. In a number of case reports published by Yamamoto et al. in 1999⁸, the tumour marker Ca72-4, was raised in both cases studied. Further studies need to clarify the validity of such a tumour marker. Ca125 can be used to monitor response to treatment and degree of disease burden, however, its use as a screening marker in Brenner tumours remains unclear.

In an analysis of 13 cases of malignant Brenner tumours, Gezginc et al.⁹, found that the overall mortality was 50%, with a mean survival time post-diagnosis of 1 year. Surgery remains the mainstay of treatment in these cases. However, since malignant Brenner tumours are rare, management relies on published case reports and remains poorly defined.

References

1. Brenner T. Das oophoroma folliculare. Frankfurt Z Pathol 1907;1:150-71.
2. Ober W B. History of the Brenner tumor of the ovary. Pathol Annu 1979;14 part 2:107-24.
3. Meyer R. Über verschiedene erscheinungsformen der als typus-Brenner bekannten eierstockgeschwulst, ihre absonderung von den granulosazelltumoren und zuordnung unter andere ovarialgeschwulste. Arch Gynaekol 1932;148:541-96
4. National Cancer Institute – Surveillance, Epidemiology and End Results Program.
5. Speert, H., 1956. Obstetrical-gynecological eponyms: Fritz Brenner and Brenner tumors of the ovary. Cancer 9, 217–21.
6. von Numers, C., 1945. A contribution to the case knowledge and histology of the Brenner tumor: do malignant forms of the Brenner tumor also occur? Acta Obstet. Gynecol. Scand. 25, 114–27.
7. Singhal VP, Chauhan N, Sharma M, Nadia S. A rare case of unilateral Brenner tumor. Int J Gynecol Plast Surg 2013;5:66-8.
8. Hull M G R, Campbell G R. The malignant Brenner tumor. Obstet Gynecol 1973;42:527-34.
9. Yamamoto et al. Malignant Brenner Tumours of the Ovary and Tumour Markers: Case Reports. *Japanese Journal of Clinical Oncology*, Volume 29, Issue 6, 1 June 1999, Pages 308–13.
10. Gezginc et al. Malignant Brenner tumour of the ovary: Analysis of 13 cases. Int J Clinical Oncology 2012; 17:324-9