

# An assessment on the use of chest imaging in children admitted with viral induced wheeze

Cecil Vella, Elizabeth Muscat

## Introduction

Viral induced wheeze in preschool children (children less than 5 years of age) is a common condition encountered by general practitioners and paediatricians worldwide. Martinez et al, in 2005 showed that approximately 25-30% of infants and young children would have at least two episodes of wheezing in early childhood. Approximately 40% will have had an episode of wheeze by the age of 3 years and almost half of them will have had at least one episode of wheezing by the age of six.<sup>1</sup> Bisgaard et al in 2006 showed in a cohort study that nearly 33% of children between the ages of 1 and 5 years suffer from wheezing associated with upper respiratory tract infections.<sup>2</sup> Fortunately, the majority tend to have only transient symptoms which resolve by five to six years of age.<sup>1</sup>

The small anatomy of the bronchi in infants results in higher peripheral airway resistance. Subsequently, respiratory illness will have proportionately greater impact on total airway resistance. In addition, infants have less elastic tissue recoil and fewer collateral airways, making them susceptible to obstruction and atelectasis. The rib cage, trachea, and bronchi are also more compliant in infants and young children. These factors make infants and young children particularly susceptible to wheezing and respiratory distress.<sup>3</sup>

## Aim

Chest radiographs are frequently performed in children presenting with viral induced wheeze. There are no local guidelines on the need for chest x-rays in infants and children presenting with wheezing associated with viral respiratory tract infections. This review was carried out to assess the frequency of chest x-rays performed and the frequency of abnormal x-rays. Chest imaging is usually performed to exclude lower respiratory tract infections. In young children with viral induced wheeze who present with tachypnoea and cough the use of chest imaging should be limited to those patients in whom a lower respiratory tract infection is strongly suspected.

## Methodology

All patients, up to five years of age presenting with a diagnosis of viral induced wheeze to the Paediatric Emergency and Admitting (E&A) department at Mater Dei Hospital Malta, between January and December 2016, were included in the review. Infants aged six months or less with a diagnosis of viral bronchiolitis were excluded. Data was collected retrospectively from an admission register. Viral induced wheeze was defined as an episode of wheeze associated with an upper respiratory tract infection in a child less than five years of age. Chest radiographs were reported by a general radiologist.

## Results

A total of 210 children were admitted to the general paediatric wards with a diagnosis of viral induced wheeze during the study period. 122 patients (58%) had a chest x-ray performed at the E&A department prior to admission. The commonest indication for performing a chest radiograph was a fever associated with the episode of wheezing. No abnormality was noted or reported in 92 (75%) of chest x-rays taken. 29 patients (25%) had a chest x-ray report ranging from mild peribronchial cuffing (86%) to collapse or consolidation

**Cecil Vella MD, MRCP(UK), FRCPC\***

Consultant Paediatrician  
Department of Paediatrics  
Mater Dei Hospital  
Msida, Malta  
cecil.vella@gov.mt

**Elizabeth Muscat MD**

FY2  
Department of Paediatrics  
Mater Dei Hospital  
Msida, Malta

*\*Corresponding Author*

(14%). Peri-bronchial cuffing is a frequent finding on chest radiographs in patients with viral bronchiolitis and bronchitis and does not signify secondary lower respiratory tract infection.

### Discussion

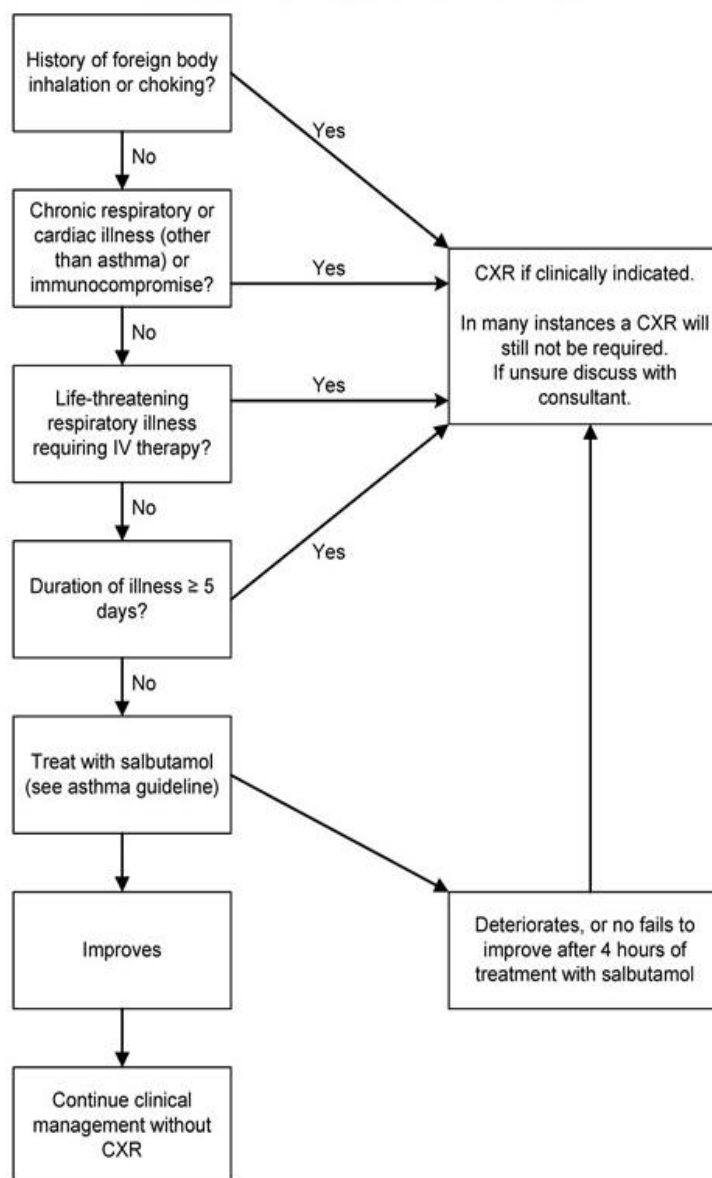
Children with recurrent viral induced wheeze frequently attend the accident and emergency department for nebulized treatment, and occasionally require admission. Chest x-rays are regularly requested, as there are no clear guidelines as to when imaging should be performed. Our review clearly shows that the vast majority of imaging requests are negative. Fever is a common presenting symptom in children with viral associated wheeze and should not be an indication for imaging unless a lower respiratory tract infection is strongly suspected from other signs or symptoms.

Despite its high prevalence, there is a lack of evidence regarding the pathophysiology, treatment and necessary investigations of viral induced wheeze. There is no evidence that chest radiographs help in the diagnosis or treatment of preschool children with acute or recurrent wheezing.<sup>4</sup> Retrospective reviews of chest x-ray use in preschool age wheeze suggested that such investigation did not contribute to the diagnosis or management of the condition.<sup>5</sup> Imaging should only be performed when a concurrent pneumonia is suspected or a suspicion of foreign body aspiration is present. In children with severe wheezing, the presence of subcutaneous emphysema or significant differences in air entry between left and right lungs should alert to the possibility of a pneumothorax and imaging should be performed.

### Conclusion

Viral induced wheeze is one of the most common conditions that requires visits to the Paediatric E&A department particularly during the winter months. Chest imaging is frequently requested but does not usually alter the management. We suggest that more attention is given prior to ordering imaging unless significant underlying pulmonary pathology is suspected in the acute phase. Children with frequent and recurrent wheezy episodes may be imaged at a later stage if underlying pulmonary pathology is suspected together with other investigations as required.<sup>6</sup>

**Figure 1:** Chest x-ray in children >6 months of age with viral induced wheeze.



Adapted from: Shepherd M., (2010) 'Chest X-ray in acute wheeze'<sup>5</sup>

### References

1. Martinez FD, Wright AL, Taussig LM, Holberg CJ, Halonen M, Morgan WJ. (1995) 'Asthma and wheezing in the first 6 years. The group Health medical associates.' *N Eng J Med.*
2. Bisgaard H. et al. (2006) 'Intermittent inhaled corticosteroids in infants with episodic wheezing' 2006 May 11;354(19):1998-2005.
3. Reisman JJ, Canny GJ, Levison H. (1993) 'Wheezing in infants and young children' In: Tinkelman DG, Naspitz CK. *Childhood Asthma: Pathophysiology and Treatment.* 2nd ed. New York, NY: Dekker; 1993:255-82.

4. Brand.P., Baraldi. E, H. Bisgaard, A. L. Boner, J. A. Castro-Rodriguez, A. Custovic, J. de Blic, J. C. de Jongste, E. Eber, M. L. Everard, U. Frey, M. Gappa, L. Garcia-Marcos, J. Grigg, W. Lenney, P. Le Souëf, S. McKenzie, P. J. F. M. Merkus, F. Midulla, J. Y. Paton, G. Piacentini, P. Pohunek, G. A. Rossi, P. Seddon, M. Silverman, P. D. Sly, S. Stick, A. Valiulis, W. M. C. van Aalderen, J. H. Wildhaber, G. Wennergren, N. Wilson, Z. Zivkovic, A. Bush (2008) 'Definition, assessment and treatment of wheezing disorders in preschool children: an evidence-based approach' *European Respiratory Journal*. Journal.32: 1096-1110.
5. Shepherd M., (2010) 'Chest X-ray in acute wheeze' *Starship children's health clinical guideline*. Current practice in the context of the National Institutes of Health guidelines. Date last published: 01 June 2010.
6. Papadopoulos NG, Kalobatsou A. 'Respiratory viruses in childhood asthma'. *Curr Opin Allergy Clin Immunol* 2007;7:91-95.